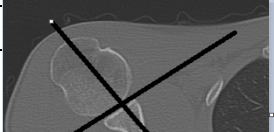
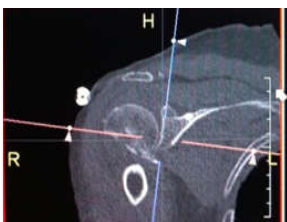

SHOULDER 16 Sensation

Indications	Pain, swelling, fall, mva, trauma					
Diagnostic Task	Detect fractures, dislocations, arthritis					
Scan mode	Helical					
Position/Landmark	Head or feet first-Supine -1CM superior to shoulder-Craniocaudal					
Topogram	Lat 140kV 100mA AP 140kV 100 mA					
kVp/Reference mass	120kv 200mas					
Rotation time/pitch	1.0/1.0					
Detector Configuration	16x0.75					
Table Speed/Increment	12					
Dose reduction	CareDose 4D					
Allowed CTDI ranges*	7mGy-50mGy					
XR29 Dose Notification value	50mGy					
Helical Set	recon	body part	thickness spacing	kernel	window	recon destination
	1	thin shoulder	.75mmx.75mm	80ultrasharp	osteo	mpr/pacs
	2	shoulder	2mmx 2mm	31medium smooth	mediastinum	pacs
	3	shoulder	.75mmx.5mm	31medium smooth	mediastinum	mpr
Scan Start/end location	1cm superior to AC joint 1cm inferior to scapula					
DFOV	25 cm decrease appropriately					
3D Technique Used	2x2 coronal and sag reformats from recon 1 bone					
	2x2 coronal and sag reformats from recon 3 soft tissue					
	do 3d spin with recon 3-if fracture seen					
IV contrast volume/type	100ml -isovue 370- if needed for soft tissue infection or mass					
Scan delay	90seconds-Performed as directed by a the supervising radiologist					
	Affect arm down by side with palm up					
	Contralateral arm above head					
	If there is a shoulder prosthesis, scan to include the distal end of the humeral component.					

Use an axial image at mid glenoid level to reformat sag and coronal reformats 2mmx2mm



Use coronal image at the mid glenoid level to reformat sag image 2mmx2mm

