

TRA-MINW

MR Peri-Anal Fistula **MR Pelvis Without & With Contrast**

Reviewed By: Anna Ellermeier, MD; Brett Mollard, MD
Last Reviewed: September 2018

Contact: (866) 761-4200

Standard uses: Primary diagnosis and evaluation of response to treatment of perianal fistula/abscess

Patient prep:

- (1) NPO for at least 4 hours prior to study
- (2) Void before examination

Coverage & coil: Phase array body coil, center of coil over pubic symphysis. Coverage is variable. See images in Appendix for guidance of inferior extent of imaging.

Intravenous contrast: Weight-based Gadavist or Multihance

Oral contrast: None

Anti-peristaltic agent: None

NOTE: See images in Appendix at end of document to help assess coverage.

Sequences:

1. 3 plane localizer
2. **Coronal T2 Ultra fast SE (HASTE, SSFSE, FASE)**
 - a. Multi-breath hold as needed
 - b. Large FOV (400-450 mm) - complete front to back coverage
 - c. Goal parameters:
 - i. Slice thickness 7-8 mm
 - ii. Gap 10-15%
3. **Sagittal T2 Ultra fast SE (HASTE, SSFSE, FASE) with fat suppression**
 - a. This series is specifically designed to determine extent of inflammatory changes (hyperintense T2 signal) and delineate coverage for following sequences
 - b. Breath hold
 - c. Large FOV, 400 mm
 - i. Approximately 20 cm above and 20 cm below anal canal
 - ii. Cover femoral head to femoral head
 - d. Goal parameters:
 - i. Slice thickness 6 mm
 - ii. Gap 10-15%
4. **Sagittal T2 fast SE (Turbo SE, Fast SE) without fat suppression**
 - a. FOV 240-320 mm, see example T2 TSE image in appendix

TRA-MINW

- i. Slices should cover entire anal canal
 - ii. Extend from pelvic sidewall to pelvic sidewall
 - b. Goal parameters
 - i. Slice thickness 3 mm
 - ii. Gap 0%
 - iii. In plane acquired resolution <1 mm
 - iv. Number of averages = 2

- 5. Oblique axial T2 fast SE (Turbo SE, Fast SE) without fat suppression, small FOV**
 - a. Plane: Imaging plane should be perpendicular to the lumen of the anal canal at the level of the sphincteric complex (See Appendix for example of scout lines for the axial series).
 - i. If question about plane or extent of coverage, call body radiologist for guidance.
 - ii. If a body radiologist is unavailable, the pubococcygeal line is a good approximation of the correct plane.
 - b. FOV 200-240 mm
 - i. Cover entire anal canal and extend in z-axis to cover all T2 hyperintense fluid or edema signal on series 3 (sagittal HASTE with fat suppression).
 - c. Goal parameters
 - i. Slice thickness 3 mm
 - ii. Gap 0%
 - iii. In plane acquired resolution <1 mm
 - iv. Number of averages = 2
 - v. Perform P→A

- 6. Oblique axial T2 fast SE (Turbo SE, Fast SE) with fat suppression, small FOV**
 - a. Plane: same as #5
 - b. FOV 200-240 mm
 - i. Cover entire anal canal and extend in z-axis to cover all T2 hyperintense fluid or edema signal on series 3 (sagittal HASTE with fat suppression).
 - c. Goal parameters
 - i. Slice thickness 3 mm
 - ii. Gap 0%
 - iii. In plane acquired resolution <1 mm
 - iv. Number of averages = 2
 - v. Perform P→A

- 7. Oblique coronal T2 fast SE (Turbo SE, Fast SE) with fat suppression, small FOV**
 - a. Plane: Perpendicular to oblique short axis in #5
 - b. FOV 200-240 mm
 - i. Cover anal canal and entire extent of inflammatory changes noted in series 3 (sagittal HASTE with fat suppression)
 - c. Goal parameters
 - i. Slice thickness 3 mm
 - ii. Gap 0%
 - iii. In plane acquired resolution <1 mm
 - iv. Number of averages = 2

- 8. Oblique short axis (axial) T1 in-phase GRE**
 - a. Plane: same as #5 (oblique short axis T2 fast SE)
 - b. FOV 200-240 mm; if this does not provide adequate SNR, sue FOV 300 mm instead
 - c. Goal parameters
 - i. Slice thickness 3 mm

TRA-MINW

- ii. Gap 0%
- iii. In plane acquired resolution <1 mm

9. Precontrast oblique short axis (axial) T1 Ultra fast 3D-GE with fat suppression (VIBE, LAVA, TIGRE)

- a. Breath hold
- b. Plane: same as #5 (oblique short axis T2 fast SE)
- c. FOV ~400 mm
- d. Goal parameters
 - i. Slice thickness 3mm
 - ii. Gap 0%
 - iii. In plane resolution approximately 1 mm x 1 mm

NOTE: Please examine entire set of precontrast VIBE images for phase or frequency encoding artifacts (e.g., hands wrapped into pelvis)

10. Postcontrast oblique short axis (axial) T1 Ultra fast 3D-GE with fat suppression (VIBE, LAVA, TIGRE) x 2

- a. Breath holds
- b. Plane: same as #5 (oblique short axis T2 fast SE)
- c. Goal parameters:
 - i. Slice thickness 3mm
 - ii. Gap 0%
- d. Timing (2 post-contrast phases)
 - i. #1 post-contrast: Acquired with center of K-space acquisition @ 45 seconds (or 40 second delay from start of injection)
 - ii. #2 post-contrast: 90 second delay

11. Postcontrast oblique coronal T1 Ultra fast 3D-GE with fat suppression (VIBE, LAVA, TIGRE)

- a. Breath hold
- b. Plane: same as #7 (oblique coronal T2 fast SE)
- c. Goal parameters:
 - i. Slice thickness 3mm
 - ii. Gap 0%
- d. Timing: 2 minute delay

12. Postcontrast true axial T1 Ultra fast 3D-GE with fat suppression (VIBE, LAVA, TIGRE)

- a. Breath hold
- b. True axial plane: no angulation
- c. Large FOV = superior iliac crest to perineum
- d. Goal parameters
 - i. Slice thickness 4-4.5mm
 - ii. In plane acquired resolution <1 mm
 - iii. Number of averages >= 2
- e. Timing: 3 minute delay (can be slightly more or less depending on patient, just to be done after #11)

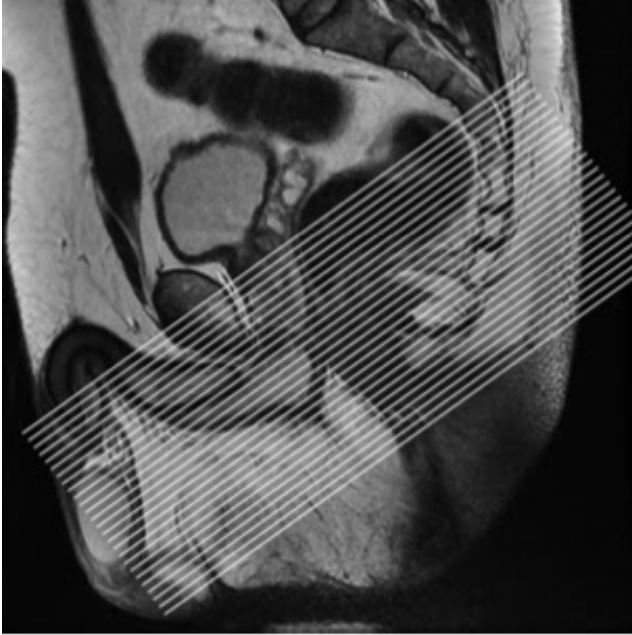13. Axial DWI large FOV

- a. Free breathing
- b. True axial plane, skin to skin coverage, iliac crests to below perineum
- c. Mandatory parameters
 - i. B-value of 0, 100, 800
 - ii. Slice thickness 8mm
 - iii. Gap 25%

TRA-MINW

Appendix

Oblique short axis of anal canal



Oblique coronal of anal canal

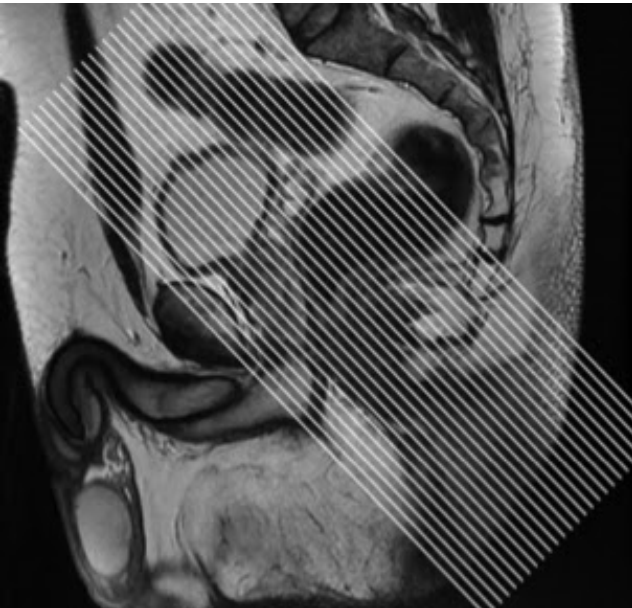


Image credits: <http://mriprotocol.blogspot.com/2012/07/perianal-fistula-imaging-planes.html>

References

1. Rectal Imaging: Part 2, Perianal Fistula Evaluation on Pelvic MRI-- What the Radiologist Needs to Know. AJR, 2012; 199; W43-53. At – <https://www.ajronline.org/doi/pdf/10.2214/AJR.11.8361>