

(EKG Gated) CTA Thoracic Aorta = CTA Chest

Reviewed By: Dan Verdini, MD, Rachael Edwards, MD

Last Reviewed: July 2019

Contact: (866) 761-4200, Option 1

In accordance with the ALARA principle, TRA policies and protocols promote the utilization of radiation dose reduction techniques for all CT examinations. For scanner/protocol combinations that allow for the use of automated exposure control and/or iterative reconstruction algorithms while maintaining diagnostic image quality, those techniques can be employed when appropriate. For examinations that require manual or fixed mA/kV settings as a result of individual patient or scanner/protocol specific factors, technologists are empowered and encouraged to adjust mA, kV or other scan parameters based on patient size (including such variables as height, weight, body mass index and/or lateral width) with the goals of reducing radiation dose and maintaining diagnostic image quality.

If any patient at a TRA outpatient facility requires re-imaging, please obtain radiologist advice prior to proceeding with exam.

The following document is an updated CT protocol for all of the sites at which TRA is responsible for the administration, quality, and interpretation of CT examinations.

Include for ALL exams

- **Scout:** Send all scouts for all cases
- **Reformats:** Made from *thinnest source* acquisition
 - Scroll Display
 - Axial recons - Cranial to caudal
 - Coronal recons - Anterior to posterior
 - Sagittal recons - Right to left
 - Chest reformats should be in separate series from Abdomen/Pelvis reformats, where applicable
- **mAs**
 - Prefer: Quality reference mAs for specific exam, scanner and patient size
 - Auto mAs, as necessary

(EKG Gated CTA) Thoracic Aorta = CTA Chest

Indication: Thoracic aortic aneurysm, aortic ectasia, aortic dissection, Thoracic EndoVascular Aortic Repair (TEVAR), etc

This CTA Thoracic Aorta protocol should be performed EKG gated as the default protocol for scanners capable of EKG gating.

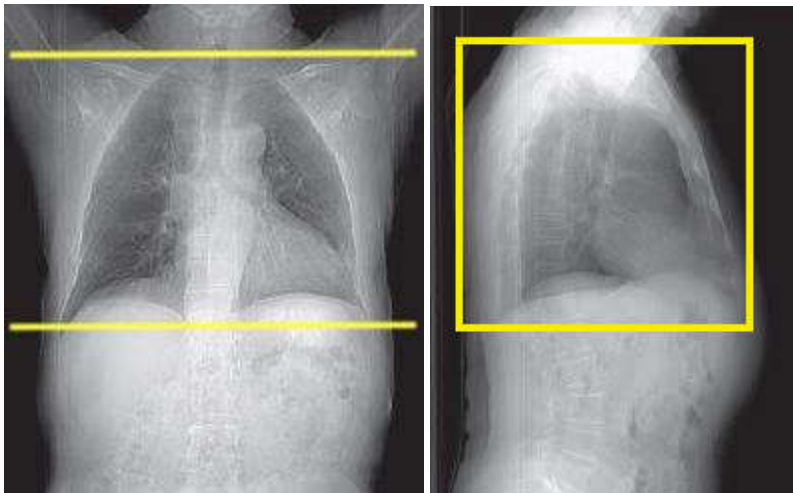
***NOTES*:**

- Ensure arterial axial recons (0.6 and 2mm) get auto-routed to TeraRecon
- **Non-contrast** phase may not be necessary if patient is < 40 yo (contact Rad)
- **Delayed phase** is needed if there is history of vascular surgery (i.e., TEVAR, or stent/graft) or for requested venous evaluation

Patient Position: Supine, feet down with arms above head

Scan Range (CC z-axis): Lung apices to aortic hiatus (where aorta crosses the diaphragm (smaller field than routine Chest CT))

****Remember, please isocenter using the lateral scout****



IV Contrast Dose, Flush, Rate and Delay:

- Dose: (modify volume if using something other than Isovue 370)
 - < 200 lbs 80 mL Isovue 370
 - > 200 lbs 100 mL Isovue 370
- Flush: 50 mL saline
- Rate: 3-4 mL/sec (20g or larger IV, at least 4 inches above wrist or pressure injectable line)

- Delay: Bolus trigger in Ascending Aorta (threshold 125HU)

Acquisitions: 1- 3 (non-contrast, arterial, delayed)

NOTES:

- Noncontrast may not be necessary in patients < 40yo (contact Rad to discuss)
- Delayed phase for patients with prior vascular surgery / endograft (s/p TEVAR) or venous evaluation
 - Breathing (all phases): End inspiration
 - kV (all phases): Scanner specified (Care kV for Siemens, BMI table for GE) or 80kV for < 150lbs, 100kV for 150 – 250 lbs, 120kV for > 250 lbs
- **Non contrast phase (if done)**
 - Coverage: lung apices through diaphragm
 - Use this exam to ensure proper coverage for arterial scan by confirming location of diaphragm hiatus (through which the aorta and esophagus travel on way to abdomen)
 - Acquisition helical thickness (slice) 1.2-1.5 mm
 - EKG gating
 - Siemens Flash: Prospective; Manual pulsing, Systolic based
 - Other scanners: Do not EKG gate
- **Arterial phase**
 - Coverage: lung apices to aortic hiatus / bottom of heart
 - Trigger bolus off ascending aorta, threshold 125 HU
 - NOTE: Use care in setting of dissection-false lumen, may require manual trigger
 - EKG Gating:
 - Siemens Flash: Prospective; Manual pulsing, Systolic based
 - Other scanners: Retrospective, Dose-modulated, Diastolic based
 - Acquisition helical thickness (slice) 0.6-625 mm
- **Delay phase (if done - patients with stent/graft, s/p TEVAR, venous evaluation)**
 - Coverage: lung apices to aortic hiatus (or further to capture the entire stent)
 - Delay of 60 seconds (or 20 seconds after arterial finishes)
 - EKG Gating:
 - Siemens Flash: Prospective; Manual pulsing, Systolic based
 - Other: Retrospective, Dose-modulated, Diastolic based
 - Acquisition helical thickness (slice) 1.2-1.5 mm

Series + Reformats:

- **Non-contrast** (if performed)
 - Axial 1.2-1.5 mm soft tissue kernel
- **Arterial**
 - Thin Axial 0.6-0.625 mm (thinnest axial recon possible) ST or Vascular kernel (***TERA RECON***)
 - Axial (not thin) 2-2.5 mm soft tissue kernel (***TERA RECON***)
 - Axial 10 x 2 mm MIP soft tissue kernel
 - Coronal 2 mm soft tissue kernel
 - Sagittal 2 mm soft tissue kernel
 - Sagittal MIP 5 x 2 aorta
 - Coronal MIP 5 x 2 aorta
- **Delay** (if performed)
 - Axial 1.2-1.5 mm soft tissue kernel

*****Machine specific protocols are included below for reference****

Machine specific recons (axial ranges given above for machine variability):

***NON-CONTRAST PHASE - Soft tissue (ST) Kernel, machine-specific thickness (axial):**

- GE = 1.25 mm
- Siemens = 1.2 mm (or 1.5 mm on older generation)
- Toshiba = 1mm

***THIN, AXIAL ARTERIAL PHASE - Soft tissue (ST) Kernel, machine-specific thickness (axial):**

- GE = 0.625 mm
- Siemens = 0.6 mm
- Toshiba = 0.625 mm

***AXIAL ARTERIAL PHASE (not thin) - Soft tissue (ST) Kernel, machine-specific thickness (axial):**

- GE = 2.5 mm
- Siemens = 2 mm
- Toshiba = 2 mm

***AXIAL DELAYED PHASE - Soft tissue (ST) Kernel, machine-specific thickness (axial):**

- GE = 1.25 mm
- Siemens = 1.2 mm (or 1.5 mm on older generation)
- Toshiba = 2 mm

***AXIAL ARTERIAL, Lung Kernel, machine-specific thickness**

- GE = 1.25 mm
- Siemens = 1.2 mm (or 1.5 mm on older generation)
- Toshiba = 2 mm

***DELAY Soft tissue (ST) Kernel, machine-specific thickness (axial):**

- GE = 1.25 mm
- Siemens = 1.2 mm (or 1.5 mm on older generation)
- Toshiba = 2 mm

General Comments

NOTE:

Use of IV contrast is preferred for most indications *aside from*: pulmonary nodule follow-up, HRCT, lung cancer screening, and in patients with a contraindication to iodinated contrast (see below).

Contrast Relative Contraindications

- **Severe contrast allergy:** anaphylaxis, laryngospasm, severe bronchospasm
 - If there is history of severe contrast allergy to IV contrast, avoid administration of oral contrast
- **Acute kidney injury (AKI):** Creatinine increase of greater than 30% over baseline
 - Reference hospital protocol (creatinine cut-off may vary)
- **Chronic kidney disease (CKD) stage 4 or 5** (eGFR < 30 mL/min per 1.73 m²) **NOT** on dialysis
 - Reference hospital protocol

Contrast Allergy Protocol

- Per hospital protocol
- Discuss with radiologist as necessary

Hydration Protocol

- For eGFR **30-45 mL/min** per 1.73 m²: Follow approved hydration protocol

IV Contrast (where indicated)

- Isovue 370 is the default intravenous contrast agent
 - See specific protocols for contrast volume and injection rate
- If Isovue 370 is unavailable:
 - Osmolality 350-370 (i.e., Omnipaque 250): Use same volume as Isovue 370
 - Osmolality 380-320 (i.e., Isovue 300, Visipaque): Use indicated volume + **25 mL** (*not to exceed 125 mL total contrast*)

Oral Contrast

- Dilutions to be performed per site/hospital policy (unless otherwise listed)
- Volumes to be given per site/hospital policy (unless otherwise listed)
- TRA-MINW document is available for reference if necessary (see website)

Brief Summary

- Chest only
 - ✓ Chest W, Chest WO
 - ✓ CTPE
 - ✓ HRCT
 - ✓ Low Dose Screening/Nodule

- None
- Pelvis only
 - ✓ Pelvis W, Pelvis WO
 - Water, full instructions as indicated
- Routine, excluding chest only and pelvis only
 - ✓ Abd W, Abd WO
 - ✓ Abd/Pel W, Abd/Pel WO
 - ✓ Chest/Abd W, Chest/Abd WO
 - ✓ Chest/Abd/Pel W, Chest/Abd/Pel WO
 - ✓ Neck/Chest/Abd/Pel W, Neck/Chest Abd Pel WO
 - ✓ CTPE + Abd/Pel W
 - TRA-MINW offices: Dilute Isovue-370
 - Hospital sites:
 - ED: Water, if possible
 - Inpatient: prefer Dilute Isovue 370
 - Gastrografin OK if Isovue unavailable
 - Avoid Barium (Readi-Cat)
 - FHS/MHS Outpatient: Gastrografin and/or Barium (Readi-Cat)
- Multiphase abdomen/pelvis
 - ✓ Liver, pancreas
 - Water, full instructions as indicated
 - ✓ Renal, adrenal
 - None
- CTA abdomen/pelvis
 - ✓ Mesenteric ischemia, acute GI bleed, endograft
 - Water, full instructions as indicated
- Enterography
 - Breeza, full instructions as indicated
- Esophogram
 - Dilute Isovue 370, full instructions as indicated
- Cystogram, Urogram
 - None

- Venogram
 - Water, full instructions as indicated